

ARTIFICIAL INTELLIGENCE ENHANCING ORTHODONTIC DIAGNOSIS AND TREATMENT

Sorana Maria BUCUR¹, Cristian Doru OLTEANU², Ioana Maria CRIȘAN^{3,*}

¹ Department of Dentistry, Faculty of Medicine, Str., 540545 Târgu-Mureș, Romania

² Department of Orthodontics, Faculty of Dental Medicine, "Iuliu Hațieganu" University of Medicine and Pharmacy, 8 Babes, Str., 400012 Cluj-Napoca, Romania;

³ "George Emil Palade" University of Medicine and Pharmacy, Sciences and Technology 540139 Târgu-Mureș, Romania

Abstract

Artificial intelligence (AI) transforms orthodontics by improving diagnostic accuracy, treatment planning, and patient monitoring. AI-based cephalometric analysis achieves 88–92% reliability, reducing human error and time consumption. In radiology, AI accounts for 85% of FDA-approved medical imaging programs, with diagnostic tools like Diagnocat reaching 92.8% precision in periapical lesion detection on CBCT. Caries and radiolucency detection AI systems report 68% to 99.2% accuracy. For skeletal age determination, AI's accuracy exceeds 90% for wrist radiographs, while cervical vertebral maturation (CVM) analysis shows variability (58–90%). AI-driven TMJ evaluation achieves sensitivity and specificity rates of 84–99.9%, enhancing osteoarthritis diagnosis. For extraction decisions, AI agrees with specialists over 80% of the time, with models reaching 93% accuracy in distinguishing extraction cases and 94% in predicting treatment needs. AI requires human oversight due to dataset limitations, algorithm unpredictability, and ethical concerns. Future developments should refine AI algorithms and improve dataset diversity to enhance clinical integration.

Keywords: artificial intelligence, orthodontics, diagnostic, treatment planning, cephalometric analysis, skeletal age determination, TMJ evaluation

Introduction

The emergence of artificial intelligence (AI) in medicine has transformed various medical specialties, including orthodontics. AI has shown promising results in improving diagnostic accuracy, planning, and predicting treatment outcomes. With the availability of various AI applications and tools, its use in orthodontic practices worldwide has increased.

This presentation explores the principles of AI, its applications in orthodontics, and its implementation in clinical practice, focusing on AI's role in dental diagnosis, cephalometric evaluation, skeletal age determination, temporomandibular joint (TMJ) assessment, decision-making, and patient telemonitoring. AI has demonstrated high efficiency in all these areas, yet performance variations and the need for human oversight call for caution in clinical settings. The complexity and unpredictability of AI algorithms require careful implementation and regular manual validation. Continuous learning with AI, proper guidance, and addressing

privacy and ethical concerns are crucial for its successful integration into orthodontic practice. Artificial intelligence (AI), a term first introduced in 1955 by John McCarthy, describes the ability of machines to perform tasks classified as intelligent [1].

Over the past 70 years, there have been cycles of significant optimism regarding AI development, alternating with periods of setbacks, research funding cuts, and skepticism [2].

The 2015 victory of AlphaGo, an application developed by Google, over the world champion in Go was a significant breakthrough [2]. This AI success against a human player sparked further development and interest, later reignited by ChatGPT's introduction in 2022. These events paved the way for the remarkable rise of AI applications across various fields, including everyday life and medicine.

AI algorithms have already proven effective in several medical specialties, surpassing the capabilities of experienced clinicians [3–7]. These algorithms enable analysis, organization, visualization, and classification of data. In recent years, the development of AI algorithms in medicine has gained momentum, particularly in radiology, where medical imaging accounts for approximately 85% of AI programs approved by the FDA (Food and Drug Administration) as of 2023.

Currently, AI's primary goals in diagnostic imaging are the detection, and segmentation of structures, and the classification of pathologies. AI tools can analyze images obtained through various imaging modalities, from X-rays to MRIs.

In diagnostic imaging, AI can be categorized into three main areas:

- ✓ Operational AI, which enhances healthcare delivery.
- ✓ Diagnostic AI, which aids in the interpretation of clinical images.
- ✓ Predictive AI, which forecasts future outcomes.

Orthodontics, with cephalometric analysis and pre-treatment imaging, are particularly well-suited for AI implementation. AI is also used in orthodontics beyond cephalometric analysis. The literature on AI in orthodontics can be categorized into five main areas:

Table 1. Main regions of A.I. in orthodontics

<i>Category</i>	<i>Description</i>
<i>Diagnosis and treatment planning</i>	AI assists in diagnosing orthodontic conditions and developing personalized treatment plans.
<i>Automatic landmark detection and cephalometric analysis</i>	AI automates the identification of cephalometric landmarks, improving accuracy and efficiency in orthodontic assessments.
<i>Growth and development assessment</i>	AI helps evaluate skeletal growth and predict developmental changes for better treatment timing.
<i>Treatment outcome evaluation</i>	AI analyzes treatment progress and predicts outcomes to enhance decision-making.
<i>Miscellaneous applications</i>	Various other AI applications, including patient telemonitoring, TMJ assessment, and ethical considerations.

The number of AI companies in the healthcare industry has seen remarkable growth, indicating a significant increase in AI's commercial prospects [9]. AI tools are no longer limited to researchers and scientists involved in R&D projects. They are now accessible through commercially available web-based products. In orthodontics, AI adoption has led to the creation of various AI-based programs, such as WeDoCeph (Audax, Ljubljana, Slovenia), WebCeph (Assemble Circle, Seoul, South Korea), and CephX (ORCA Dental AI, Las Vegas, NV, USA). These systems can automatically identify cephalometric landmarks, calculate angles and distances, and generate cephalometric reports with significant findings. AI programs are now easily accessible on mobile devices, making AI tools widely available and promoting equal access for all interested users. As a result, orthodontic practices and researchers using AI applications have increased significantly. This accessibility has also raised concerns about patient safety, especially when AI is used for diagnosis and treatment.

Diagnosis

The emergence of artificial intelligence (AI) in medicine has transformed various medical specialties, including orthodontics. AI has shown promising results in improving diagnostic accuracy, planning, and predicting treatment outcomes. Its use in orthodontic practices worldwide has increased with the availability of various AI applications and tools [8].

This presentation explores the principles of AI, its applications in orthodontics, and its advantages.

Medical imaging plays a crucial role in diagnosing dental pathologies. Radiological methods such as OPG and CBCT are essential for orthodontic evaluation, but the increasing imaging needs AI-based diagnostic support.

Diagnocat Ltd. (San Francisco, USA) has developed an AI-driven diagnostic system for tooth segmentation, pathology detection, and volumetric assessment. Studies confirm its high accuracy, with Orhan et al. reporting 92.8% precision in periapical lesion detection on CBCT. However, some studies question AI's effectiveness in OPG evaluations.

Ezhov (2021) compared diagnostic accuracy in CBCT analysis between AI-assisted and non-assisted groups. AI significantly improved sensitivity (0.8537 vs. 0.7672) and specificity (0.9672 vs. 0.9616). Meta-analyses suggest multimodal AI systems can enhance diagnostic workflows, particularly in caries and radiolucency detection, where accuracy varies from 68% to 99.2% [9].

Cephalometric analysis

Cephalometric analysis (CA), used in orthodontics since 1931, has evolved from manual tracing to digital automation. AI-driven systems enhance efficiency by improving landmark identification, reducing human error, and minimizing time consumption. Studies since 1998 confirm AI's reliability of 88% - 92% [10].

CBCT-based CA, initially impractical due to inefficiency, has gained traction with advancements in AI. Artificial neural networks (ANNs) match or exceed human performance in landmark identification. However, manual validation remains necessary. A 2023 study found an average 2.44 mm deviation between AI-generated and manual 3D landmarks [11].

Skeletal age determination

Growth assessment is vital in orthodontics, as treatment success depends on skeletal maturity rather than chronological age. CVM and wrist radiographs are commonly used for evaluation, with AI proving effective in skeletal age prediction. Despite accuracy rates exceeding 90% for wrist X-rays, AI's performance in CVM analysis remains inconsistent, with agreement rates ranging from 58% to over 90% [12].

Studies highlight potential errors due to limited expert input in establishing diagnostic standards. A recent systematic review found model accuracy between 50% and 90%, emphasizing the need for more robust datasets. AI's role in skeletal maturity assessment is promising but still developing. Skeletal age assessment is crucial in orthodontics for tailoring treatment plans to an individual's developmental stage. Several methods are employed to estimate skeletal maturity.

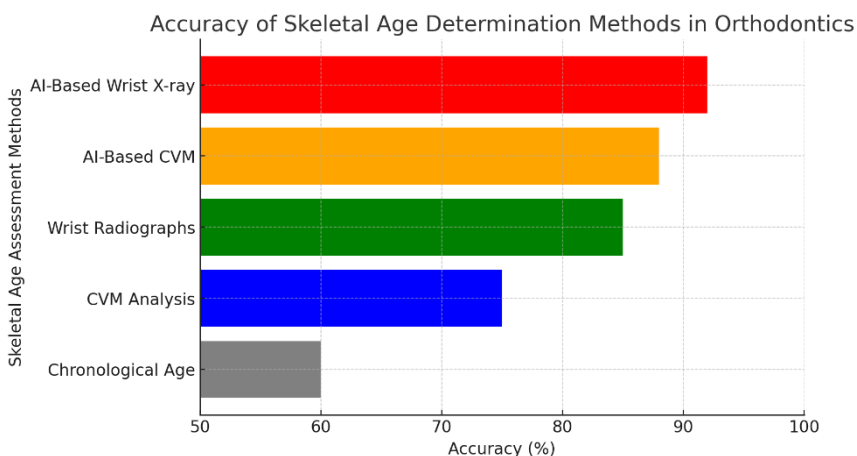


Fig 2. Skeletal age determination methods

CBCT-based CA, initially impractical due to inefficiency, has gained traction with advancements in AI. Artificial neural networks (ANNs) match or exceed human performance in landmark identification. However, manual validation remains necessary. A 2023 study found an average 2.44 mm deviation between AI-generated and manual 3D landmarks [13].

Chronological Age Estimation uses a person's actual age to infer developmental status. However, due to individual variations in growth, chronological age may not accurately reflect skeletal maturity. Studies have shown discrepancies between chronological age and skeletal development, suggesting more precise assessment tools.

Cervical Vertebral Maturation (CVM) Analysis evaluates the maturation stages of cervical vertebrae using lateral cephalometric radiographs, which are commonly taken in orthodontic assessments. This method offers the advantage of not requiring additional radiation exposure. Research indicates that CVM analysis is a reliable indicator of skeletal maturity, correlating well with other methods like hand-wrist radiographs [14].

Assessing skeletal age through hand-wrist radiographs involves comparing the ossification of hand and wrist bones to standard growth charts, such as the Greulich and Pyle atlas. This technique has been a traditional standard in evaluating skeletal development. Studies have demonstrated its validity, though it requires additional radiographic exposure [15].

Artificial intelligence has been integrated into CVM analysis to enhance accuracy and efficiency. AI algorithms can automatically identify and assess cervical vertebral stages from cephalometric images, reducing observer variability. Recent studies have shown that AI-assisted CVM analysis provides results comparable to human examiners, offering a promising tool for clinical practice [16].

Similarly, AI applications in analyzing wrist radiographs aim to automate the assessment of skeletal maturity. These systems utilize machine learning to evaluate bone development stages accurately. While AI-based wrist analysis shows potential, further research is needed to validate its effectiveness across diverse populations [17].

In summary, while traditional methods like CVM and wrist radiograph analyses are well-established, the incorporation of AI offers advancements in precision and efficiency for skeletal age determination in orthodontics.

TMJ Evaluation

Temporomandibular joint osteoarthritis (TMJOA) affects joint function, causing pain, malocclusion, and asymmetry. OPG/CBCT imaging detects bone changes, while MRI assesses soft tissues. AI has demonstrated high diagnostic accuracy in TMJOA detection, staging, and masticatory muscle disorders, with reported sensitivity and specificity between 84% and 99.9%.

AI-driven TMJ analysis could enhance early diagnosis and personalized osteoarthritis treatment, offering an efficient alternative to traditional imaging methods.

Determining the need for extraction

Deciding whether to proceed with tooth extractions in orthodontic treatment is a complex process influenced by multiple factors. These include the nature of the dental issue, patient expectations, cultural perspectives, and the orthodontist's clinical approach. Experience, education, and treatment philosophy also play significant roles, making extraction decisions challenging even for seasoned professionals. Notably, expert opinions can differ considerably, particularly in borderline cases.

AI-based tools have been developed to assist in this decision-making process, showing promising accuracy in mimicking expert judgments. Studies have reported that AI models have over 80% agreement with orthodontic specialists.

One study demonstrated a 93% success rate in distinguishing extraction from non-extraction cases using 12 cephalometric variables, while another reported 84% accuracy in identifying specific extraction patterns. Further research found AI predictions to be 94% accurate for extraction decisions, 84.2% for identifying extraction patterns, and 92.8% for anchorage needs [12]. Factors in predicting treatment success included dental crowding, incisor inclination, overbite, overjet, and lip competence.

However, these AI-driven models have limitations. Since they are trained in expert decisions, they may reflect specific clinical philosophies rather than universally validated approaches. Additionally, crucial dental factors—such as extensive restorations, periodontal health, periapical lesions, and missing teeth—are often overlooked. Given these constraints, it remains difficult to fully rely on AI for extraction decisions, particularly in borderline cases.

While AI tools provide valuable support, orthodontists must carefully assess each case. Over-reliance on automated decision-making may lead to treatment plans that align more with a particular clinical philosophy rather than individualized patient needs. A balanced approach, integrating AI insights with professional expertise, ensures the best outcomes for orthodontic patients.

Conclusions

Artificial intelligence (AI) in orthodontics has brought significant advancements in diagnostic accuracy, treatment planning, and patient monitoring. AI has proven effective in automating cephalometric analysis, assisting in skeletal age determination, evaluating temporomandibular joint (TMJ) disorders, and supporting clinical decision-making. These applications reduce human error and provide a more standardized approach to orthodontic assessments.

AI-based cephalometric analysis has demonstrated reliability comparable to clinicians, reducing time consumption while maintaining diagnostic accuracy. Similarly, AI's role in skeletal age assessment, particularly through cervical vertebral maturation (CVM) analysis and wrist radiographs, presents a promising alternative to traditional methods.

The use of AI in TMJ evaluation has shown high sensitivity and specificity in detecting osteoarthritic changes and soft tissue disorders, suggesting its viability as an adjunct diagnostic tool. Moreover, AI-driven decision-making in treatment planning, particularly in extraction assessments, has achieved high accuracy in the need for extractions and anchorage considerations. However, AI models are inherently limited by their dependence on training datasets, which may reflect specific clinical philosophies rather than universally applicable guidelines.

Despite these advances, AI remains a complementary tool rather than a replacement for clinical expertise. The unpredictability of AI algorithms, the need for manual validation, concerns regarding patient data privacy, and ethical considerations must be carefully addressed. AI-driven orthodontics requires continuous human oversight to ensure that diagnostic and treatment recommendations align with individual patient needs.

Future developments should focus on refining AI algorithms, increasing dataset diversity, and integrating AI seamlessly into clinical workflows. As AI evolves, a balanced approach—leveraging AI's efficiency while maintaining the orthodontist's critical judgment—will be essential in optimizing patient outcomes and advancing orthodontic care.

References

1. Amisha, Malik P, Pathania M, Rathaur VK. *Overview of artificial intelligence in medicine.* **J Family Med Prim Care.** 2019. 8, 7. 2328-31. doi: 10.4103/jfmpc.jfmpc_440_19.

2. Ding H, Wu J, Zhao W, Matinlinna JP, Burrow MF, Tsoi JKH. *Artificial intelligence in dentistry-A review*. **Front Dent Med**. 2023. 20, 4:1085251. doi: 10.3389/fdmed.2023.
3. Krishnan G, Singh S, Pathania M, Gosavi S, Abhishek S, Parchani A, Dhar M. *Artificial intelligence in clinical medicine: catalyzing a sustainable global healthcare paradigm*. **Front Artif Intell**. 2023. 29, 6:1227091. doi: 10.3389/frai.2023.1227091.
4. Alowais SA, Alghamdi SS, Alsuhebany N, Alqahtani T, Alshaya AI, Almohareb SN, Aldairem A, Alrashed M, Bin Saleh K, Badreldin HA, Al Yami MS, Al Harbi S, Albekairy AM. *Revolutionizing healthcare: the role of artificial intelligence in clinical practice*. **BMC Med Educ**. 2023. 23. 689. doi: 10.1186/s12909-023-04698-z.
5. Bohr A, Memarzadeh K. *The rise of artificial intelligence in healthcare applications*. **Artificial Intelligence in Healthcare**. 2020. 25. 60. doi: 10.1016/B978-0-12-818438-7.00002-2.
6. Bekbolatova M, Mayer J, Ong CW, Toma M. *Transformative Potential of AI in Healthcare: Definitions, Applications, and Navigating the Ethical Landscape and Public Perspectives*. **Healthcare (Basel)**. 2024. 12, 2. 125. doi: 10.3390/healthcare12020125.
7. Čartolovni A, Malešević A, Poslon L. *Critical analysis of the AI impact on the patient-physician relationship: A multi-stakeholder qualitative study*. **Digit Health**. 2023. 9:20552076231220833. doi: 10.1177/20552076231220833.
8. Popa SL, Ismaiel A, Brata VD, Turtoi DC, Barsan M, Czako Z, Pop C, Muresan L, Stanculete MF, Dumitrascu DI. *Artificial Intelligence and medical specialties: support or substitution?* **Med Pharm Rep**. 2024. 97, 4. 409-18. doi: 10.15386/mpr-2696.
9. Kazimierczak N, Kazimierczak W, Serafin Z, Nowicki P, Nożewski J, Janiszewska-Olszowska J. *AI in Orthodontics: Revolutionizing Diagnostics and Treatment Planning-A Comprehensive Review*. **J Clin Med**. 2024. 13, 2. 344. doi: 10.3390/jcm13020344.
10. Hendrickx J, Gracea RS, Vanheers M, Winderickx N, Preda F, Shujaat S, Jacobs R. *Can artificial intelligence-driven cephalometric analysis replace manual tracing? A systematic review and meta-analysis*. **Eur J Orthod**. 2024. 46, 4:cjae029. doi: 10.1093/ejo/cjae029.
11. Serafin M, Baldini B, Cabitza F, Carrafiello G, Baselli G, Del Fabbro M, Sforza C, Caprioglio A, Tartaglia GM. *Accuracy of automated 3D cephalometric landmarks by deep learning algorithms: systematic review and meta-analysis*. **Radiol Med**. 2023. 128, 5. 544-55. doi: 10.1007/s11547-023-01629-2.
12. Liu J, Zhang C, Shan Z. *Application of Artificial Intelligence in Orthodontics: Current State and Future Perspectives*. **Healthcare (Basel)**. 2023. 11, 20:2760. doi: 10.3390/healthcare11202760.
13. Lee JH, Lee NK, Zou B, Park JH, Choi TH. *Reliability of Artificial Intelligence-based Cone Beam Computed Tomography Integration with Digital Dental Images*. **J Vis Exp**. 2024. 204. doi: 10.3791/66014.
14. Durka-Zajac M, Marcinkowska A, Mituś-Kenig M. *Bone age assessment using cephalometric photographs*. **Pol J Radiol**. 2013. 78, 2. 19-25. doi: 10.12659/PJR.889072.
15. Suri S, Prasad C, Tompson B, Lou W. *Longitudinal comparison of skeletal age determined by the Greulich and Pyle method and chronologic age in normally growing children, and clinical interpretations for orthodontics*. **Am J Orthod Dentofacial Orthop**. 2013. 143, 1. 50-60. doi: 10.1016/j.ajodo.2012.08.027.

16. Kirschneck C, Proff P. *Age assessment in orthodontics and general dentistry. Quintessence Int.* 2018. 49, 4. 313-23. doi: 10.3290/j.qi.a39960.
17. Shamsoddin E, Moradi F. *Validity of age estimation methods and reproducibility of bone/dental maturity indices for chronological age estimation. Evid Based Dent.* 2023. 24, 1. 15-16. doi: 10.1038/s41432-023-00856-w.
18. Hack M, Hack L, Bucur SM, Delean AG, Nedelcu E, Dragulin B, Stan D, Gruia V, Păcurar M. *Comparative Study on the Guidance of Orthodontic Treatments through Artificial Intelligence-Based Software and Classic Software. Romanian J Oral Rehabil.* 2023. 15, 4. 436-48. <https://rjor.ro/comparative-study-on-the-guidance-of-orthodontic-treatments-through-artificial-intelligence-based-software-and-classic-software/>
19. Thirumoorthy S, Gopal S. *Diagnostic accuracy of AI in orthodontic extraction decisions: "Are we ready to let Mr. Data run our Enterprise?" A commentary on a systematic review. Evid Based Dent.* 2023. 24, 1. 17-18. doi: 10.1038/s41432-023-00865-9.
20. Köktürk B, Pamukçu H, Gözüaçık Ö. *Evaluation of different machine learning algorithms for extraction decision in orthodontic treatment. Orthod Craniofac Res.* 2024. Suppl 2. 13-24. doi: 10.1111/ocr.12811.

Received: January 11, 2025

Accepted: March 05, 2025